



Review Article



Adjuvant Therapy for Hepatocellular Carcinoma After Curative Treatment: Several Unanswered Questions

Le Li^{1,2#}, Zhen-Zhen Li^{3#}, Li-Xin Pan¹, Jia-Yong Su¹, Shan Huang¹, Liang Ma^{1*} and Jian-Hong Zhong^{1,4,5*}

¹Hepatobiliary Surgery Department, Guangxi Medical University Cancer Hospital, Nanning, Guangxi, China; ²Guangxi Academy of Medical Sciences, Emergency Department, The People's Hospital of Guangxi Zhuang Autonomous Region, Nanning, Guangxi, China; ³Pathology Department, Guangxi Medical University Cancer Hospital, Nanning, Guangxi, China; ⁴Key Laboratory of Early Prevention and Treatment for Regional High Frequency Tumor (Guangxi Medical University), Ministry of Education, Nanning, Guangxi, China; ⁵Guangxi Key Laboratory of Early Prevention and Treatment for Regional High Frequency Tumor, Nanning, Guangxi, China

Received: 19 January 2024 | Revised: 31 March 2024 | Accepted: 9 April 2024 | Published online: 24 April, 2024

Abstract

Most patients with hepatocellular carcinoma (HCC) have a poor prognosis. Hepatectomy and local ablation are the main curative treatments for HCC. Nevertheless, the recurrence rate after hepatectomy or ablation is up to 70%, which seriously affects patient prognosis. Several adjuvant therapies have been explored to reduce postoperative recurrence. However, although a variety of adjuvant therapies have been shown to reduce the recurrence rate and improve overall survival, a standard consensus of national HCC guidelines for adjuvant treatment is lacking. Therefore, there are significant differences in the recommendations for adjuvant therapy for HCC between the Eastern and Western guidelines. A variety of adjuvant treatment methods, such as antiviral therapy, transarterial chemoembolization or traditional Chinese medicine, are recommended by the Chinese HCC guidelines. However, Western guidelines make few recommendations other than antiviral therapy. Adjuvant immune checkpoint inhibitors are recommended only in the recently updated American Association for the Study of Liver Diseases guidelines. This review summarized the existing adjuvant therapy options after curative hepatectomy or ablation and discusses several important dilemmas of adjuvant treatments.

Citation of this article: Li L, Li ZZ, Pan LX, Su JY, Huang S, Ma L, et al. Adjuvant Therapy for Hepatocellular Carcinoma After Curative Treatment: Several Unanswered Questions. *J Clin Transl Hepatol* 2024. doi: 10.14218/JCTH.2024.00030.

Keywords: Hepatocellular carcinoma; Adjuvant therapy; Curative hepatectomy; Recurrence; Overall survival; Immune checkpoint inhibitor.

Abbreviations: BCLC, Barcelona Clinic Liver Cancer; HBV, chronic hepatitis B virus; HCC, hepatocellular carcinoma; HCV, hepatitis C virus; HAIC, hepatic arterial infusion chemotherapy; ICI, immune checkpoint inhibitor; MVI, microvascular invasion; OS, overall survival; RFS, recurrence-free survival; TACE, transarterial chemoembolization; VK2, vitamin K2 analogs.

#Contributed equally to this work.

***Correspondence to:** Jian-Hong Zhong, Guangxi Medical University Cancer Hospital, He Di Rd. #71, Nanning, Guangxi 530021, China. ORCID: <https://orcid.org/0000-0002-1494-6396>. Tel: +86-771-5301253, Fax: +86-771-5312000, E-mail: zhongjianhong@gxmu.edu.cn; Liang Ma, Hepatobiliary Surgery Department, Guangxi Medical University Cancer Hospital, Nanning, Guangxi 530021, China. ORCID: <https://orcid.org/0000-0001-8106-373X>, Tel: +86-771-5301253, Fax: +86-771-5312000, E-mail: maliangxyd@163.com.

Introduction

Hepatocellular carcinoma (HCC) is one of the most common malignancies and the third leading cause of cancer death, with increasing morbidity and mortality in recent years.¹ Currently, liver transplantation, hepatectomy or local ablation are the main curative therapies for early HCC. Hepatectomy is recommended in some Asian countries for intermediate or advanced HCC patients with well-preserved liver function.^{2,3} Theoretically, liver transplantation is the best curative option for HCC but it has limitations in that patients with well-preserved liver function or not satisfying the Milan criteria are not eligible. More important, there is a serious shortage of liver donors. Therefore, hepatectomy and local ablation are still considered to be the main curative treatment options.

In fact, a majority of HCCs are not easy to be detected and diagnosed at the early stage due to a lack of typical symptoms and signs.⁴⁻⁶ Once typical clinical manifestations occur, the disease has usually progressed to an intermediate or advanced stage.⁷ Even after hepatectomy, the overall survival (OS) of HCC patients remains very poor because of postoperative recurrence and/or metastasis. It has been reported that the 5-year recurrence rate of HCC after curative hepatectomy is not more than 70%.^{8,9} Even for HCC patients with very early/early stage Barcelona Clinic Liver Cancer (BCLC), the 5-year recurrence rate is 59.3% after hepatectomy and 70.6% after local ablation.¹⁰ Therefore, effective preventive measures are urgently needed to reduce recurrence and improve OS after hepatectomy or local ablation.

Many studies have reported the efficacy of various adjuvant therapies in reducing recurrence after hepatectomy or local ablation. Currently, evidence-based medicine in support of adjuvant therapy for HCC is not sufficient, and different countries or regions have different recommendations. In this review, we summarize the existing evidence of adjuvant therapy for HCC after curative hepatectomy or ablation and discuss several urgent dilemmas in adjuvant treatment (Fig. 1).

Prospective trials, prospective cohort studies, and meta-analyses that explored the efficacy of adjuvant therapies to prevent HCC recurrence in patients following curative hepatectomy or local ablation indexed through December 30,

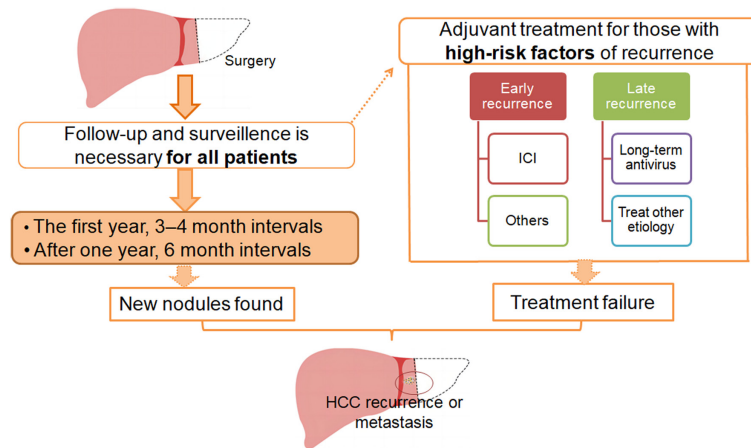


Fig. 1. Follow-up and surveillance, recurrent modality, and adjuvant treatment strategy in patients with hepatocellular carcinoma (HCC) after curative hepatectomy or local ablation. ICI, immune checkpoint inhibitor.

2023 in the PubMed database (<https://pubmed.ncbi.nlm.nih.gov/>) were identified. The keywords "hepatocellular carcinoma", "hepatectomy", "surgery", "hepatic resection", "ablation", "postoperative", and "adjuvant" were used. Additional papers were identified by manually searching the references of identified studies. Only prospective research and meta-analyses published in English were considered. This review focused on the outcomes of OS and recurrence-free survival (RFS).

Unanswered Questions of Adjuvant Treatment

Who will benefit from adjuvant treatment?

Postoperative adjuvant therapy is necessary because of the high recurrence rate of HCC. However, at present, there is no widely recognized adjuvant treatment modality with clear efficacy. Therefore, it is obviously unreasonable for HCC patients who are tumor-free after curative hepatectomy or local ablation to receive adjuvant therapy. Adjuvant therapy will certainly cause adverse events and increase treatment costs, but it may not significantly reduce the postoperative recurrent rate. Almost all randomized trials that have been published^{11–13} or are^{14–16} currently ongoing recruited HCC patients at high risk of recurrence after curative hepatectomy or local ablation. Official guidelines also recommend that HCC patients at high risk of recurrence are eligible to participate in clinical trials and receive adjuvant therapy.^{2,3,17} Therefore, only patients at high risk of recurrence receive adjuvant therapy.

What are the risk factors for recurrence?

HCC recurrence is generally believed to have two origins. One is the single-center origin in which intrahepatic micro-metastases of the primary tumor or microthrombi before or after hepatectomy. This kind of recurrence usually occurs within 2 years after initial curative treatment, and is termed an early recurrence. The other is the multicenter origin, which occurs late, usually more than 2 years after surgery. Patients with late recurrence have a significantly better prognosis than those with early recurrence, which means that different types of recurrence have different risk factors.^{18,19} Many studies indicated the main risk factors of early-phase recurrence include tumor size more than 5 cm, multiple tumors, satellites, absence of a tumor capsule, tumor rupture,

non-anatomical resection, narrow resection margin (≤ 2 cm), alpha-fetoprotein ≥ 400 ng/mL, as well as micro- and macrovascular invasion. In randomized trials, high-risk features for hepatectomy patients included tumor size > 5 cm, more than three tumors, microvascular invasion (MVI), macrovascular invasion, and poor tumor differentiation.^{11–16} Risk factors of late-phase recurrence included liver cirrhosis, higher grade of hepatitis activity, and poor tumor classification.^{20–22} HCC patients usually have underlying chronic liver disease or cirrhosis caused by chronic hepatitis B virus (HBV) or hepatitis C virus (HCV) infection, alcoholic, or nonalcoholic steatohepatitis.²³ They thus always have early and late phase recurrence risk factors.

The existence of high-risk recurrence factors means that the probability of residual tumor in the remanent liver is higher and the possibility of early recurrence is greater, which seriously affects the overall effectiveness of surgical treatment and patient quality of life. Adjuvant therapy after local treatment of HCC aims to reduce the recurrence rate and thus increase RFS and OS. In fact, local (hepatectomy or ablation) and adjuvant treatment can be complementary. On one hand, local treatment reduces tumor burden and induces the release of tumor antigens and pro-inflammatory cytokines. On the other hand, adjuvant immunotherapy and tyrosine kinase inhibitors can boost antitumor immunity. The different risk factors for the two types of recurrence suggest that different targets should be targeted when designing adjuvant therapy. For intrahepatic metastasis, the primary strategy should target disseminated tumor cells that have spread from the primary tumor, just as in transarterial chemoembolization (TACE). For *de novo* carcinogenesis, the strategy is to control the progression of hepatitis or cirrhosis, as in antiviral treatment.²⁴ The effective elimination of residual tumors or prevention of intrahepatic metastasis with adjuvant therapy can help reduce early recurrence, which may be a reason that adjuvant therapy is more suitable for patients with high-risk factors of recurrence. However, few studies have shown that postoperative antiproliferative and anti-angiogenic therapy reduce latent intrahepatic and extrahepatic spread, which is often associated with the risk of early recurrence.

What are the strategies for adjuvant therapy?

Antiviral therapy: There are multiple goals for antiviral therapy in patients with hepatitis-related HCC. On the ba-

sis of comprehensive treatment of HCC, antiviral therapy maximizes long-term inhibition of virus replication, reduces liver damage caused by the virus, prevents disease progression, provides a good basis for liver function, reduces the risk of postoperative recurrence, and ultimately prolongs patient survival.^{25,26} In HCV-related HCC, sustained viral eradication obtained by interferon-based or interferon-free regimens significantly reduces tumor recurrence without differences associated with the antiviral strategy used.²⁷ However, a meta-analysis showed that recurrence risk and survival were extremely variable in patients with successfully treated HCV-related HCC, providing a useful benchmark for indirect comparison of the benefits of direct-acting antivirals.²⁸ In addition, a high HBV load has been associated with poor RFS and OS in patients with HCC after hepatectomy.^{21,29} Therefore, antiviral therapy is crucial for preventing postoperative recurrence of HBV- or HCV-related HCC.

Nucleos(t)ide analogs: Several randomized trials reported the positive efficacy of postoperative treatment with nucleos(t)ide analogs for HBV-related HCC, with reduced viral load, decreased tumor recurrence, and improved OS. A meta-analysis of 21 studies including 8,752 patients explored the efficacy of nucleos(t)ide analogs for patients with HBV-related HCC after curative hepatectomy. It found that postoperative nucleos(t)ide analog therapy significantly reduced early recurrence rate and improved OS.³⁰ The use of nucleos(t)ide analogs for postoperative HBV-related HCC is recommended by several HCC treatment guidelines.^{2,17,31}

Nucleos(t)ide analogs include lamivudine, adefovir dipivoxil, entecavir, tenofovir, and others. Previous study found adefovir dipivoxil and lamivudine were associated with similar survival benefits in patients with HBV-related HCC after curative hepatectomy, and that adefovir dipivoxil was more cost-effective.³² Tenofovir has been associated with significantly lower HCC risk than entecavir in patients with chronic HBV infection who are from Asia and/or nucleos(t)ide naïve.^{33,34} A recent randomized trial including patients with HBV-related HCC after curative hepatectomy, reported that consistent tenofovir therapy was associated with a significantly lower risk of tumor recurrence than entecavir therapy.³⁵ Moreover, when compared with entecavir, tenofovir decreased serum lipoprotein levels in patients with HBV-related HCC.³⁶ Antiviral therapy with tenofovir may thus be the preferred drug for HBV-related HCC after curative treatment.³⁷

Interferon: Many studies reported the safety and efficacy of interferon in the prevention of recurrence after curative hepatectomy for HCC, but with different conclusions. Interferon has various functions such as antiviral replication, antitumor angiogenesis, regulating cell proliferation, immune regulation, and blocking proto-oncogenes. Eight randomized trials reported the safety and efficacy of interferon in preventing postoperative HCC recurrence, of which three enrolled only patients with HCV-related HCC,³⁸⁻⁴⁰ one enrolled only HBV-related HCC,⁴¹ and the other four included patients with either HBV- or HCV-related HCC.⁴²⁻⁴⁵ The reasons for these differences may be heterogeneity of the underlying liver disease and liver reserve function, as well as interferon type, dose, and duration of treatment. A meta-analysis of these eight RCTs concluded that interferon reduced the 2-year recurrence rate and improved the 2-year OS after curative hepatectomy.⁴⁶ However, another meta-analysis showed that adjuvant interferon was effective in prolonging RFS and OS of HCV-related HCC but not HBV-related HCC, showing that the effectiveness of interferon was different in different populations and viral-related HCC.⁴⁷ Although adjuvant interferon therapy may be effective, it is associated

with many adverse reactions, including fatigue, chills, fever, headache, muscle pain, leukopenia, and thrombocytopenia. Other less common adverse reactions include transaminase elevation and alopecia.

TACE or hepatic arterial infusion chemotherapy: TACE is a key treatment of intermediate-stage HCC. The main purpose of adjuvant TACE is to eradicate tumor cells that may have been released during the intraoperative extrusion and to destroy preexisting microscopic cancer foci that preoperative imaging failed to detect. Randomized trials and retrospective studies with large sample sizes have confirmed that adjuvant TACE reduced the intrahepatic recurrence rate and improved RFS and/or OS after resection.^{11,12,48} None of these trials included patients who underwent local ablation. A meta-analysis had shown a survival benefit with adjuvant TACE.⁴⁹ Another meta-analysis including 11,165 patients showed that adjuvant TACE significantly improved RFS and OS compared with curative resection alone. A subgroup analysis showed that adjuvant TACE was more effective in patients with tumor maximum diameters of >5 cm, MVI, and multiple tumors, but had the opposite effects in early HCC patients without MVI, and even decreased RFS.⁵⁰ The most frequent adverse events of TACE include fever, nausea, ascites, fatigue, leukopenia, and liver function damage. Most patients tolerate it without requiring need symptomatic treatment. All these randomized trials were from China or Japan. The HCC guidelines in Western countries do not recommend adjuvant TACE for HCC.^{17,51}

Hepatic arterial infusion chemotherapy (HAIC) is administered by continuous infusion of chemotherapy drugs into tumor blood vessels with microcatheters. HAIC has the advantages of higher local drug concentration and fewer systemic side effects than systemic chemotherapy. HAIC alone or in combination with immunotherapy or molecular targeted therapy has shown surprising effects in advanced HCC.⁵²⁻⁵⁴ A randomized trial enrolled 315 HCC patients with MVI who underwent hepatectomy followed by adjuvant HAIC or routine follow-up. Adjuvant HAIC with FOLFOX significantly improved RFS with acceptable toxicity in HCC patients with MVI.⁵⁵ However, these findings need to be confirmed by further trials.

During the implementation of TACE and HAIC, digital subtraction angiography (DSA) is required before the drug is injected. DSA can detect residual lesions and determine whether hepatectomy was curative or not. In cases with residual lesions, the purpose of TACE or HAIC is to control residual lesions (so-called recurrence foci). These treatments are not adjuvant therapy. Owing to the absence of DSA detection in the active surveillance group, residual lesions were not found in time. Those who did not achieve genuine curative treatment did not receive TACE or HAIC therapy for residual lesions, and their short-term recurrence rate was significantly higher than that in the treatment group. Although some randomized trials included curative cases, they did not report the specific criteria of "curative". In addition, those randomized trials did not exclude some cases enrolled after DSA, such as those with residual lesions during imaging. Therefore, the conclusion that adjuvant TACE or HAIC significantly reduced the recurrence rate after curative hepatic resection may not be accurate. If real curative cases were included, positive results might not have been observed. We look forward to RCTs that include genuine curative cases to explore this issue.

Molecular targeted drugs: Whether sorafenib should be used as adjuvant therapy for HCC after curative resection remains controversial. The STORM study explored the safety and efficacy of adjuvant sorafenib treatment of HCC

Table 1. Ongoing phase III clinical trials of adjuvant immune checkpoint inhibitors after hepatectomy or ablation

Trials	ClinicalTrials.gov ID	Sample (n)	Tumor status	Treatment arms	Primary endpoint
CheckMate 9DX	NCT03383458	545	High-risk recurrence	Nivolumab vs. placebo	RFS
EMERALD-2	NCT03847428	908	High-risk recurrence	Durvalumab + bevacizumab vs. durvalumab vs. placebo	RFS
IMbrave 050	NCT04102098	668	High-risk recurrence	Atezolizumab + bevacizumab vs. active surveillance	RFS*
KEYNOTE-937	NCT03867084	950	BCLC 0 or A	Pembrolizumab vs. placebo	RFS, OS
JUPITER 04	NCT03859128	402	High-risk recurrence	Toripalimab vs. placebo	RFS
SHR-1210-III-325	NCT04639180	687	High-risk recurrence	Camrelizumab + apatinib vs. active surveillance	RFS

*Interim analysis was reported. BCLC, Barcelona Clinic Liver Cancer; OS, overall survival; RFS, recurrence-free survival.

following resection or ablation. The study noted no difference in median RFS in the sorafenib (33.3 months) and placebo groups (33.7 months). Moreover, sorafenib increased the rate of grade 3 or 4 adverse events.¹³ It is noted that the STORM trial only enrolled a few proportions of patients with a high risk of recurrence. Randomized trials exploring the safety and efficacy of other tyrosine kinase inhibitors (e.g., lenvatinib, apatinib, or donafinib) as adjuvant therapy for HCC after curative hepatectomy are ongoing.

Immunotherapy: Immunotherapy is a therapeutic method of killing tumor cells by stimulating or regulating immune function. Currently, immunotherapy for HCC mainly includes adoptive immunotherapy, immune checkpoint inhibitors (ICIs), tumor vaccines, and others. Several randomized trials have confirmed the safety and efficacy of adjuvant adoptive immunotherapy for patients with HCC after hepatectomy.⁵⁶⁻⁵⁹ These findings were confirmed by meta-analyses.^{60,61}

ICIs are an emerging treatment with great potential for effective treatment of HCC. The success of the IMbrave150 study has laid a solid foundation for the combined use of ICI therapy for advanced HCC.⁶² A phase II trial with a single arm (n=55) including patients with intermediate or high risk of recurrence who received adjuvant nivolumab had a median RFS of 26 months, but most patients had single tumors with a median diameter of approximately 2.6 cm and no vascular invasion.⁶³ A prospective cohort study included 432 patients receiving no adjuvant therapy (83.6%), 53 (10.2%) who received ICIs alone, and 32 (6.2%) who received adjuvant ICIs plus tyrosine kinase inhibitors. During a median follow-up of 34.0 months, propensity score matching found that RFS and OS were significantly higher in patients who received either type of adjuvant therapy than in those who received no adjuvant therapy. More interestingly, the study found no significant differences in RFS or OS between patients treated with ICIs alone or ICIs with tyrosine kinase inhibitors. The overall study findings imply that ICIs alone or combined with tyrosine kinase inhibitors improved RFS in patients at high risk of HCC recurrence after curative hepatectomy.⁶⁴ Recently, an interim analysis of IMbrave050 (n=668) reported that at a median follow-up of 17.4 months, adjuvant atezolizumab plus bevacizumab were associated with a significantly lower RFS rate than active surveillance in patients with HCC and a high risk of recurrence ($p=0.012$). However, the median RFS of both groups had not been reached.⁶⁵ Longer follow-up is needed to confirm the efficacy of adjuvant atezolizumab plus bevacizumab. Other randomized trials are currently underway, including CheckMate 9DX,¹⁴ KEYNOTE-937,¹⁵ and EMERALD-2¹⁶ (Table 1). We are looking forward to the reporting

of the trial results.

Systemic chemotherapy: Theoretically, systemic chemotherapy can control tumor growth and reduce recurrence by killing tumor cells in the blood circulation. However, randomized trials did not find capecitabine or uracil tegafur significantly improved RFS or OS.⁶⁶⁻⁶⁸ A small randomized trial (n=60) found that postoperative adjuvant capecitabine therapy significantly reduced the risk of tumor recurrence in HCC patients after hepatectomy, but did not improve OS.⁶⁹ However, a meta-analysis found no significant benefit of adjuvant oral systemic chemotherapy on OS and RFS.⁷⁰ Moreover, the adverse events of systemic chemotherapy included transaminase elevation, nausea, diarrhea, and bone marrow suppression.

Radiation therapy: Radiotherapy has gradually become one of the main treatment methods for unresectable HCC.^{71,72} However, the efficacy of adjuvant radiotherapy for HCC after curative hepatectomy remains controversial. A randomized trial (n=119) found that adjuvant radiotherapy was technically feasible and relatively safe for centrally located HCCs after narrow-margin hepatectomy but did not improve RFS and OS.⁷³ A phase II trial included 76 HCC patients who underwent narrow-margin hepatectomy and then received postoperative intensity-modulated radiotherapy. During a median follow-up of 70 months, the 5-year OS and RFS rates were 72.2% and 51.6%, respectively. No marginal recurrence was found. The most common radiation-associated grade-3 toxicity was leukopenia (7.9%).⁷⁴ A systematic review including 10 studies (three randomized trials, one phase II trial, and six retrospective comparative studies) found adjuvant external beam radiotherapy significantly improved RFS and OS compared with hepatectomy alone.⁷⁵ Therefore, the current limited evidence showed that adjuvant radiotherapy was a safe and effective measure to prevent HCC recurrence.

A small randomized trial (n=43) found adjuvant intra-arterial iodine-131 labeled significantly improved RFS and OS in patients with HCC after curative hepatectomy.^{76,77} However, a larger randomized trial (n=103) did not find a clinical benefit of adjuvant iodine-131 for such patients.⁷⁸ Therefore, the efficacy of adjuvant iodine-131 in HCC needs to be confirmed by more randomized trials with large samples.

Vitamin K2 analogs: Vitamin K2 analogs (VK2) have been shown to induce cell cycle arrest at the G1/S phase leading to growth inhibition of HCC cells and to have potent anti-angiogenic activity, preventing late recurrence.⁷⁹ Five randomized trials and one cohort study from Japan reported the controversial efficacy of adjuvant oral VK2 in preventing HCC recurrence and improving survival after curative hepatectomy or ablation.⁸⁰⁻⁸⁵ A meta-analysis of those studies

found that adjuvant VK2 analogs reduced short-term tumor recurrence and improved short-term OS.⁸⁶ It is noted that the included populations were from Japan. The role of VK2 analogs in other countries or regions remains to be explored.

Traditional Chinese medicine: Chen *et al.*⁸⁷ performed a multicenter randomized trial of the efficacy of adjuvant Huaier on long-term prognosis after curative hepatectomy. A total of 1,044 patients with HCC after hepatectomy were randomly assigned to receive Huaier or placebo in a 2:1 ratio. RFS was significantly prolonged and extrahepatic recurrence was reduced in the treatment group. The molecular mechanism of Huaier needs further exploration.

When is adjuvant treatment administered?

Although many retrospective or prospective studies have reported the application of adjuvant therapy for HCC, the start time of adjuvant therapy is not uniform. In most randomized trials, the general recommended date of initial adjuvant therapy is 4–8 weeks. The difference between HCC patients and those with other malignant tumors is that HCC develops combined with liver diseases, such as cirrhosis, liver function abnormalities, and others. Therefore, in addition to the recovery of systemic conditions, the date of initial adjuvant therapy for HCC should also be combined with the recovery of postoperative liver function and comorbidities, such as hypertension and diabetes.

Different recommendations for adjuvant therapy in different countries

Although many randomized trials have explored the efficacy of adjuvant therapy, the findings are different, or the same treatment can lead to inconsistent or even opposite findings. Therefore, recommendations for adjuvant therapy differ greatly in the HCC treatment guidelines in different countries (Table 2). There is an East-West consensus regarding the use of nucleos(t)ide analogs for postoperative treatment of patients with HBV-related HCC. The Chinese guidelines recommend adjuvant TACE and Huaier for HCC patients with a high risk of recurrence (Level 1, Strong Recommendation).² In contrast, the recommendations of HCC guidelines in other countries are conservative. The Korean HCC guidelines recommend adjuvant adoptive immunotherapy after curative hepatectomy⁸⁸ and the Japanese guidelines only recommend antiviral therapy for patients with viral hepatitis.³ The National Comprehensive Cancer Network guidelines state that no adjuvant therapies have been shown to have benefits but there are ongoing clinical trials.⁸⁹ The American Association for the Study of Liver Diseases recommends the use of adjuvant ICI-based systemic therapy in patients at a high risk of recurrence after hepatectomy or local ablation (Level 2, Strong Recommendation).¹⁷ However, the European Association for the Study of the Liver and the European Society for Medical Oncology do not recommend any adjuvant therapy for HCC.^{51,90} As medicine evolves and clinical trials are successful, the gaps in the guidelines for adjuvant therapy will be filled.

There are many reasons why the recommendations of HCC guidelines in different countries or regions may vary greatly. The first is the difference in treatment philosophy. The treatment model recommended by Chinese HCC guidelines presents a multi-treatment model in which one treatment method can be applied to multiple tumor stages. For example, hepatic resection can be applied to stages Ia to IIIa HCC. Tumors of the same stage can receive a variety of treatments. For example, patients with intermediate or advanced HCC can receive transarterial treatment combined with targeting and immunotherapy. In Western guidelines, a

combination treatment model is rarely recommended. Second, Western guidelines attach great importance to quality control at the level of evidence. Only high-level evidence-based treatment would be cited in Western guidelines. Finally, most official HCC guidelines, but not those in China, detail each author's conflict of interest.

Discussion

Although many adjuvant therapies for HCC after hepatectomy or local ablation have been reported, no treatment consensus has been reached. Adjuvant TACE may significantly reduce intrahepatic recurrence and improve OS, but only in patients with a high risk of recurrence, such as tumors >5 cm in diameter, multiple tumors, or those involving micro- or macrovascular invasion.⁴⁹ It has also been reported that adjuvant HAIC may be beneficial in patients with MVI.⁵⁵ However, further randomized trials that included genuine curative cases are needed to explore the efficacy of adjuvant TACE or HAIC. A series of randomized trials have shown that antiviral therapy has potential benefits in reducing the recurrence rate and improving RFS and/or OS in patients with viral hepatitis-related HCC after curative hepatectomy or local ablation. Reliable and sufficient high-level evidence has verified this finding. Although the STORM trial reached a negative conclusion, it is not yet possible to conclude that molecular-targeted agents have no role in the adjuvant therapy of HCC. The efficacy of other adjuvant therapies such as radiolabeled lipiodol, radiotherapy, VK2 analogs, retinoids, and heparanase inhibitors has been shown to a certain extent, but they are not routinely used in clinical practice and need to be further verified in large randomized trials. Early trials have found adjuvant immunotherapy has to be effective in HCC. Many randomized trials of adjuvant ICIs in HCC are ongoing, and the results of these trials are worth looking forward to. Although many randomized trials have reported a variety of effective adjuvant treatment options, there are still many open questions worthy of clinical consideration, such as who will benefit most from adjuvant treatment, when adjuvant treatment is administered, which adjuvant treatment options are optimal, how about reliable multiparametric biomarkers of adjuvant therapy response, and so on.^{91–93} Last but not least, combination regimens, such as TACE or HAIC combined with targeted drugs, ICIs, or radiotherapy, or a combination of targeted agents plus ICIs, is also a direction of adjuvant therapy being explored.⁹⁴

The purpose of adjuvant therapy is to reduce the risk of postoperative recurrence, thereby reducing the recurrence rate and thus prolonging survival. However, there is no standard stratification of recurrence risk,^{95,96} and various studies of adjuvant therapy for HCC enrolled populations that differed in recurrence risk. Factors such as viral infection, alpha-fetoprotein level, liver cirrhosis, tumor size, satellite nodules, multiple tumors, and micro- or macrovascular invasion may indicate a high risk of recurrence after hepatectomy or local ablation.^{22,97} Stratification of high-risk recurrence is also defined differently in different countries, which may lead to significant differences in the effectiveness of different adjuvant treatment regimens and subsequent recommendations in different countries. Integrating these risk factors to identify those at high risk of recurrence and those who could potentially benefit from adjuvant therapy after HCC remains a challenge. In recent years, molecular-targeted drugs and ICIs are emerging and have shown initial efficacy in HCC. In the future, the use of combination therapy such as ICIs combined with molecular targeted drugs and/or TACE will most likely increase.

Table 2. Recommendation of adjuvant therapy for hepatocellular carcinoma in various countries or regions

Treatment option	EASL 2018	ESMO 2018	AASLD 2023	NCCN 2023	CNLC 2022	JSH 2021	KLCA 2022
Nucleoside analogs							
Interferon	Not recommended	Not recommended	Not recommended	Not recommended	Level 1, Moderate recommendation	Not recommended	Not recommended
TACE	Not recommended	Not recommended	Not recommended	Not recommended	Level 1, Strong recommendation	Not recommended	Not recommended
HAIC	Not recommended	Not recommended	Not recommended	Not recommended	Exploring	Not recommended	Not recommended
TKIs	Not recommended	Not recommended	Not recommended	Not recommended	Exploring	Not recommended	Not recommended
ICIs	Clinical trials	Not recommended	Level 2, Strong recommendation	Clinical trials	Exploring	Not recommended	Not recommended
Adoptive immunotherapy	Not recommended	Not recommended	Not recommended	Not recommended	Not described	Not recommended	CIK cell (Level 2, Strong recommendation)
Systemic chemotherapy	Not recommended	Not recommended	Not recommended	Not recommended	Not described	Not recommended	Not recommended
Radiation therapy	Not recommended	Not recommended	Not recommended	Not recommended	Level 2, Moderate/Weak recommendation	Not recommended	Not recommended
Vitamin analogs and retinoids	Not recommended	Not recommended	Not recommended	Not recommended	Not described	Not recommended	Not recommended
Heparanase inhibitors	Not recommended	Not recommended	Not recommended	Not recommended	Not described	Not recommended	Not recommended
Huaier	Not described	Not described	Not described	Not described	Level 1, Strong recommendation	Not described	Not described

AASLD, American Association for the Study of Liver Diseases; CNLC, China National Liver Cancer; EASL, European Association for the Study of the Liver; ESMO, European Society for Medical Oncology; HAIC, hepatic arterial infusion chemotherapy; ICIs, immune checkpoint inhibitors; JSH, Japan Society of Hepatology; KLCA, Korean Liver Cancer Association; NCCN, National Comprehensive Cancer Network; TACE, transarterial chemoembolization; TKI, tyrosine kinase inhibitor.

Acknowledgments

We thank the authors of the cited references for their excellent work.

Funding

This work was supported by the Specific Research Project of Guangxi for Research Bases and Talents (GuiKe AD22035057), Guangxi Key Research and Development Plan Project (GuiKe AB24010082), Guangxi TCM appropriate technology development and promotion project (GZSY23-66), and the Key Laboratory of Early Prevention and Treatment for Regional High Frequency Tumor (Guangxi Medical University), Ministry of Education (GKE-ZZ202217 and GKE-ZZ202311).

Conflict of interest

JHZ has been an Editorial Board Member of *Journal of Clinical and Translational Hepatology* since 2020. The other authors have no conflict of interests related to this publication.

Author contributions

Conceived the study (JHZ), acquired and analyzed the data (All authors), drafted and revised the manuscript (LL, JHZ), read the manuscript and approved the final version to be published (All authors), and had full access to all the data in the study and serves as guarantor, taking full responsibility for the integrity of the data and the accuracy of the data analysis (JHZ).

References

- [1] Siegel RL, Miller KD, Wagle NS, Jemal A. Cancer statistics, 2023. *CA Cancer J Clin* 2023;73(1):17–48. doi:10.3322/caac.21763, PMID:36633525.
- [2] Zhou J, Sun H, Wang Z, Cong W, Wang J, Zeng M, *et al*. Guidelines for the Diagnosis and Treatment of Hepatocellular Carcinoma (2019 Edition). *Liver Cancer* 2020;9(6):682–720. doi:10.1159/000509424, PMID:33442540.
- [3] Kudo M, Kawamura Y, Hasegawa K, Tateishi R, Kariyama K, Shiina S, *et al*. Management of Hepatocellular Carcinoma in Japan: JSH Consensus Statements and Recommendations 2021 Update. *Liver Cancer* 2021;10(3):181–223. doi:10.1159/000514174, PMID:34239808.
- [4] Ahn JC, Lee YT, Agopian VG, Zhu Y, You S, Tseng HR, *et al*. Hepatocellular carcinoma surveillance: current practice and future directions. *Hepatoma Res* 2022;8:10. doi:10.20517/2394-5079.2021.131, PMID:36161213.
- [5] Theresa JH, Daniel JC, Daniel HP, Omar E, Philip JJ, Rashika F, *et al*. Ultrasonography in surveillance for hepatocellular carcinoma in patients with non-alcoholic fatty liver disease. *Hepatoma Res* 2023;9:12. doi:10.20517/2394-5079.2022.97.
- [6] Kara W, Anna Mae D, Cynthia AM. Challenges and barriers in hepatocellular carcinoma (HCC) surveillance for patients with non-alcoholic fatty liver disease (NAFLD). *Hepatoma Res* 2023;9:11. doi:10.20517/2394-5079.2022.92.
- [7] Zhong JH, Peng NF, You XM, Ma L, Xiang X, Wang YY, *et al*. Tumor stage and primary treatment of hepatocellular carcinoma at a large tertiary hospital in China: A real-world study. *Oncotarget* 2017;8(11):18296–18302. doi:10.18632/oncotarget.15433, PMID:28407686.
- [8] Zhong JH, Xing BC, Zhang WG, Chan AW, Chong CCN, Serenari M, *et al*. Repeat hepatic resection versus radiofrequency ablation for recurrent hepatocellular carcinoma: retrospective multicentre study. *Br J Surg* 2021;109(1):71–78. doi:10.1093/bjs/znac340, PMID:34643677.
- [9] Yuan BH, Zhu YK, Zou XM, Zhou HD, Li RH, Zhong JH. Repeat hepatic resection versus percutaneous ablation for the treatment of recurrent hepatocellular carcinoma: meta-analysis. *BJS Open* 2022;6(2):zrac036. doi:10.1093/bjsopen/zrac036, PMID:35482024.
- [10] Wang JH, Wang CC, Hung CH, Chen CL, Lu SN. Survival comparison between surgical resection and radiofrequency ablation for patients in BCLC very early/early stage hepatocellular carcinoma. *J Hepatol* 2012;56(2):412–418. doi:10.1016/j.jhep.2011.05.020, PMID:21756858.
- [11] Wang Z, Ren Z, Chen Y, Hu J, Yang G, Yu L, *et al*. Adjuvant Transarterial Chemoembolization for HBV-Related Hepatocellular Carcinoma After Resection: A Randomized Controlled Study. *Clin Cancer Res* 2018;24(9):2074–2081. doi:10.1158/1078-0432.CCR-17-2899, PMID:29420221.
- [12] Wei W, Jian PE, Li SH, Guo ZX, Zhang YF, Ling YH, *et al*. Adjuvant transcatheter arterial chemoembolization after curative resection for hepatocellular carcinoma patients with solitary tumor and microvascular invasion: a randomized clinical trial of efficacy and safety. *Cancer Commun (Lond)* 2018;38(1):61. doi:10.1186/s40880-018-0331-y, PMID:30305149.
- [13] Bruix J, Takayama T, Mazzaferro V, Chau GY, Yang J, Kudo M, *et al*. Adjuvant sorafenib for hepatocellular carcinoma after resection or ablation (STORM): a phase 3, randomised, double-blind, placebo-controlled trial. *Lancet Oncol* 2015;16(13):1344–1354. doi:10.1016/S1470-2045(15)00198-9, PMID:26361969.
- [14] Jimenez Exposito MJ, Akce M, Montero Alvarez JL, Assenat E, Balart LA, Baron AD, *et al*. CA209-9DX: phase III, randomized, double-blind study of adjuvant nivolumab vs placebo for patients with hepatocellular carcinoma (HCC) at high risk of recurrence after curative resection or ablation. *Ann Oncol* 2018;29(Suppl 8):viii267–viii268. doi:10.1093/annonc/mdy432.059.
- [15] Vogel A, Zhu AX, Cheng AL, Yau T, Zhou J, Kim E, *et al*. KEYNOTE-937 trial in progress: adjuvant pembrolizumab in patients with hepatocellular carcinoma (HCC) and complete radiologic response after surgical resection or local ablation. *Ann Oncol* 2020;31(Suppl 4):S703. doi:10.1016/j.annonc.2020.08.1132.
- [16] Knox J, Cheng A, Cleary S, Galle P, Kokudo N, Lencioni R, *et al*. A phase 3 study of durvalumab with or without bevacizumab as adjuvant therapy in patients with hepatocellular carcinoma (HCC) who are at high risk of recurrence after curative hepatic resection. *Ann Oncol* 2019;30(Suppl 4):iv51. doi:10.1093/annonc/mdz155.216.
- [17] Singal AG, Llovet JM, Yarrow M, Mehta N, Heimbach JK, Dawson LA, *et al*. AASLD Practice Guidance on prevention, diagnosis, and treatment of hepatocellular carcinoma. *Hepatology* 2023;78(6):1922–1965. doi:10.1097/HEP.000000000000466, PMID:37199193.
- [18] Wei T, Zhang XF, Bagante F, Ratti F, Marques HP, Silva S, *et al*. Early Versus Late Recurrence of Hepatocellular Carcinoma After Surgical Resection Based on Post-recurrence Survival: an International Multi-institutional Analysis. *J Gastrointest Surg* 2021;25(1):125–133. doi:10.1007/s11605-020-04553-2, PMID:32128681.
- [19] Wang MD, Li C, Liang L, Xing H, Sun LY, Quan B, *et al*. Early and Late Recurrence of Hepatitis B Virus-Associated Hepatocellular Carcinoma. *Oncologist* 2020;25(10):e1541–e1551. doi:10.1634/theoncologist.2019-0944, PMID:32472951.
- [20] Li Z, Tan C, Liu X, Feng Z, Li K. Early and late recurrence after hepatectomy in patients with low-level HBV-DNA hepatocellular carcinoma under antiviral therapy. *Infect Agent Cancer* 2022;17(1):56. doi:10.1186/s13027-022-00468-6, PMID:36397089.
- [21] Wu JC, Huang YH, Chau GY, Su CW, Lai CR, Lee PC, *et al*. Risk factors for early and late recurrence in hepatitis B-related hepatocellular carcinoma. *J Hepatol* 2009;51(5):890–897. doi:10.1016/j.jhep.2009.07.009, PMID:19747749.
- [22] Xu XF, Xing H, Han J, Li ZL, Lau WY, Zhou YH, *et al*. Risk Factors, Patterns, and Outcomes of Late Recurrence After Liver Resection for Hepatocellular Carcinoma: A Multicenter Study From China. *JAMA Surg* 2019;154(3):209–217. doi:10.1001/jamasurg.2018.4334, PMID:30422241.
- [23] Su JY, Deng ZJ, Teng YX, Koh YX, Zhang WG, Zheng MH, *et al*. Prognosis after hepatic resection of patients with hepatocellular carcinoma related to non-alcoholic fatty liver disease: meta-analysis. *BJS Open* 2023;7(1):zrac167. doi:10.1093/bjsopen/zrac167, PMID:36802244.
- [24] Zhong JH, Ma L, Li LQ. Postoperative Antiviral Therapy With Nucleos(t)ide Analogs in Patients With Hepatitis B Virus-Related Hepatocellular Carcinoma. *Ann Surg* 2017;265(4):e46–e47. doi:10.1097/SLA.0000000000001224, PMID:28266988.
- [25] Massimo F, Mariacristina P, Michele M, Francesco Rosario Paolo I, Marianna C, Bruno C, *et al*. Risk of hepatocellular carcinoma development in long-term nucleos(t)ide analog suppressed patients with chronic hepatitis B. *Hepatoma Res* 2023;9:3. doi:10.20517/2394-5079.2022.51.
- [26] Zhou J, Wang FD, Li LQ, Li YJ, Wang SY, Chen EQ. Antiviral Therapy Favors a Lower Risk of Liver Cirrhosis in HBeAg-negative Chronic Hepatitis B with Normal Alanine Transaminase and HBV DNA Positivity. *J Clin Transl Hepatol* 2023;11(7):1465–1475. doi:10.14218/JCTH.2023.00272, PMID:38161505.
- [27] Petta S, Cabibbo G, Barbara M, Attardo S, Bucci L, Farinati F, *et al*. LI.CA) Group. Hepatocellular carcinoma recurrence in patients with curative resection or ablation: impact of HCV eradication does not depend on the use of interferon. *Aliment Pharmacol Ther* 2017;45(1):160–168. doi:10.1111/apt.13821, PMID:27790734.
- [28] Cabibbo G, Petta S, Barbara M, Missale G, Virdone R, Caturelli E, *et al*. A meta-analysis of single HCV-untreated arm of studies evaluating outcomes after curative treatments of HCV-related hepatocellular carcinoma. *Liver Int* 2017;37(8):1157–1166. doi:10.1111/liv.13357, PMID:28061016.
- [29] Yang T, Lu JH, Zhai J, Lin C, Yang GS, Zhao RH, *et al*. High viral load is associated with poor overall and recurrence-free survival of hepatitis B virus-related hepatocellular carcinoma after curative resection: a prospective cohort study. *Eur J Surg Oncol* 2012;38(8):683–691. doi:10.1016/j.ejso.2012.04.010, PMID:22621971.
- [30] Zhang G, Yu X, Liu P, Huang X, Jiang X. Efficacy of Nucleoside Analogs for Chronic Hepatitis B Virus-Related Hepatocellular Carcinoma After Curative Treatment: A Meta-Analysis. *Dig Dis Sci* 2018;63(12):3207–3219. doi:10.1007/s10620-018-5252-8, PMID:30140982.
- [31] Omata M, Cheng AL, Kokudo N, Kudo M, Lee JM, Jia J, *et al*. Asia-Pacific clinical practice guidelines on the management of hepatocellular carcinoma: a 2017 update. *Hepatol Int* 2017;11(4):317–370. doi:10.1007/s12072-017-9799-9, PMID:28620797.
- [32] Zhong JH, Ke Y, Zhu SL, Wang L, Luo CP, Gong WF, *et al*. Adefovir dipivoxil is less expensive than lamivudine and associated with similar prognosis in patients with hepatitis B virus-related hepatocellular carcinoma after radical resection. *Onco Targets Ther* 2016;9:6897–6907. doi:10.2147/OTT.S120062, PMID:27877054.
- [33] Yuan BH, Li RH, Huo RR, Li MJ, Papatheodoridis G, Zhong JH. Lower risk

- of hepatocellular carcinoma with tenofovir than entecavir treatment in subsets of chronic hepatitis B patients: an updated meta-analysis. *J Gastroenterol Hepatol* 2022;37(5):782–794. doi:10.1111/jgh.15783, PMID: 35080052.
- [34] Teng YX, Li MJ, Xiang BD, Zhong JH. Tenofovir may be superior to entecavir for preventing hepatocellular carcinoma and mortality in individuals chronically infected with HBV: a meta-analysis. *Gut* 2020;69(10):1900–1902. doi:10.1136/gutjnl-2019-320326, PMID:31843789.
- [35] Linye H, Zijing X, Xiaoyun Z, Zhihui L, Tianfu W, Chuan L. Tenofovir versus entecavir on the prognosis of hepatitis B-related hepatocellular carcinoma after surgical resection: a randomised controlled trial. *Int J Surg* 2023;109(10):3032–3041. doi:10.1097/JS9.0000000000000554, PMID: 37335984.
- [36] Su JY, Wu YL, Wu XL, Liu ZX, Wang YY, Li ZH, et al. Letter: Entecavir versus tenofovir on serum lipoprotein levels of hepatitis B virus-related hepatocellular carcinoma after curative hepatectomy. *Aliment Pharmacol Ther* 2023;58(8):842–844. doi:10.1111/apt.17668, PMID:37768294.
- [37] Pan LX, Wang YY, Li ZH, Luo JX, Wu KJ, Liu ZX, et al. Entecavir versus tenofovir for prevention of hepatitis B virus-associated hepatocellular carcinoma after curative resection: study protocol for a randomized, open-label trial. *Trials* 2024;25(1):25. doi:10.1186/s13063-023-07742-x, PMID:38183137.
- [38] Ikeda K, Arase Y, Saitoh S, Kobayashi M, Suzuki Y, Suzuki F, et al. Interferon beta prevents recurrence of hepatocellular carcinoma after complete resection or ablation of the primary tumor—A prospective randomized study of hepatitis C virus-related liver cancer. *Hepatology* 2000;32(2):228–232. doi:10.1053/jhep.2000.9409, PMID:10915728.
- [39] Kubo S, Nishiguchi S, Hirohashi K, Tanaka H, Shuto T, Kinoshita H. Randomized clinical trial of long-term outcome after resection of hepatitis C virus-related hepatocellular carcinoma by postoperative interferon therapy. *Br J Surg* 2002;89(4):418–422. doi:10.1046/j.0007-1323.2001.02054.x, PMID:11952580.
- [40] Shiratori Y, Shiina S, Teratani T, Imamura M, Obi S, Sato S, et al. Interferon therapy after tumor ablation improves prognosis in patients with hepatocellular carcinoma associated with hepatitis C virus. *Ann Intern Med* 2003;138(4):299–306. doi:10.7326/0003-4819-138-4-200302180-00008, PMID:12585827.
- [41] Sun HC, Tang ZY, Wang L, Qin LX, Ma ZC, Ye QH, et al. Postoperative interferon alpha treatment postponed recurrence and improved overall survival in patients after curative resection of HBV-related hepatocellular carcinoma: a randomized clinical trial. *J Cancer Res Clin Oncol* 2006;132(7):458–465. doi:10.1007/s00432-006-0091-y, PMID:16557381.
- [42] Mazzaferro V, Romito R, Schiavo M, Mariani L, Camerini T, Bhoori S, et al. Prevention of hepatocellular carcinoma recurrence with alpha-interferon after liver resection in HCV cirrhosis. *Hepatology* 2006;44(6):1543–1554. doi:10.1002/hep.21415, PMID:17133492.
- [43] Lo CM, Liu CL, Chan SC, Lam CM, Poon RT, Ng IO, et al. A randomized, controlled trial of postoperative adjuvant interferon therapy after resection of hepatocellular carcinoma. *Ann Surg* 2007;245(6):831–842. doi:10.1097/01.sla.0000245829.00977.45, PMID:17522506.
- [44] Chen LT, Chen MF, Li LA, Lee PH, Jeng LB, Lin DY, et al. Long-term results of a randomized, observation-controlled, phase III trial of adjuvant interferon Alfa-2b in hepatocellular carcinoma after curative resection. *Ann Surg* 2012;255(1):8–17. doi:10.1097/SLA.0b013e3182363ff9, PMID:22104564.
- [45] Lin SM, Lin CJ, Hsu CW, Tai DI, Sheen IS, Lin DY, et al. Prospective randomized controlled study of interferon-alpha in preventing hepatocellular carcinoma recurrence after medical ablation therapy for primary tumors. *Cancer* 2004;100(2):376–382. doi:10.1002/cncr.20004, PMID:14716774.
- [46] Zhong JH, Li H, Li LQ, You XM, Zhang Y, Zhao YN, et al. Adjuvant therapy options following curative treatment of hepatocellular carcinoma: a systematic review of randomized trials. *Eur J Surg Oncol* 2012;38(4):286–295. doi:10.1016/j.ejso.2012.01.006, PMID:22281155.
- [47] Xu JB, Qi FZ, Xu G, Chen GF, Huang MD, Zhang JH. Adjuvant interferon therapy after surgical treatment for hepatitis B/C virus-related hepatocellular carcinoma: A meta-analysis. *Hepatol Res* 2014;44(2):209–217. doi:10.1111/hepr.12109, PMID:23578168.
- [48] Qi YP, Zhong JH, Liang ZY, Zhang J, Chen B, Chen CZ, et al. Adjuvant transarterial chemoembolization for patients with hepatocellular carcinoma involving microvascular invasion. *Am J Surg* 2019;217(4):739–744. doi:10.1016/j.amjsurg.2018.07.054, PMID:30103903.
- [49] Zhong JH, Li LQ. Postoperative adjuvant transarterial chemoembolization for participants with hepatocellular carcinoma: A meta-analysis. *Hepatol Res* 2010;40(10):943–953. doi:10.1111/j.1872-034X.2010.00710.x, PMID:20887328.
- [50] Chen W, Ma T, Zhang J, Zhang X, Chen W, Shen Y, et al. A systematic review and meta-analysis of adjuvant transarterial chemoembolization after curative resection for patients with hepatocellular carcinoma. *HPB (Oxford)* 2020;22(6):795–808. doi:10.1016/j.hpb.2019.12.013, PMID:31980307.
- [51] European Association for the Study of the Liver. EASL Clinical Practice Guidelines: Management of hepatocellular carcinoma. *J Hepatol* 2018;69(1):182–236. doi:10.1016/j.jhep.2018.03.019, PMID:29628281.
- [52] Lyu N, Wang X, Li JB, Lai JF, Chen QF, Li SL, et al. Arterial Chemotherapy of Oxaliplatin Plus Fluorouracil Versus Sorafenib in Advanced Hepatocellular Carcinoma: A Biomolecular Exploratory, Randomized, Phase III Trial (FO-HAIC-1). *J Clin Oncol* 2022;40(5):468–480. doi:10.1200/JCO.21.01963, PMID:34905388.
- [53] Lai Z, He M, Bu X, Xu Y, Huang Y, Wen D, et al. Lenvatinib, toripalimab plus hepatic arterial infusion chemotherapy in patients with high-risk advanced hepatocellular carcinoma: A biomolecular exploratory, phase II trial. *Eur J Cancer* 2022;174:68–77. doi:10.1016/j.ejca.2022.07.005, PMID:35981413.
- [54] Zhong JH, Chen ZS, Qi L, Zhang ZM, Xiang BD, Ma L. A retrospective study exploring the safety and efficacy of hepatic arterial infusion chemotherapy and sequential transarterial embolization combined with lenvatinib and tislelizumab in unresectable hepatocellular carcinoma. *J Clin Oncol* 2023;41(16_suppl):e16219. doi:10.1200/JCO.2023.41.16_suppl.e16219.
- [55] Li SH, Mei J, Cheng Y, Li Q, Wang QX, Fang CK, et al. Postoperative Adjuvant Hepatic Arterial Infusion Chemotherapy With FOLFOX in Hepatocellular Carcinoma With Microvascular Invasion: A Multicenter, Phase III, Randomized Study. *J Clin Oncol* 2023;41(10):1898–1908. doi:10.1200/JCO.22.01142, PMID:36525610.
- [56] Takayama T, Sekine T, Makuuchi M, Yamasaki S, Kosuge T, Yamamoto J, et al. Adoptive immunotherapy to lower postsurgical recurrence rates of hepatocellular carcinoma: a randomized trial. *Lancet* 2000;356(9232):802–807. doi:10.1016/S0140-6736(00)02654-4, PMID:11022927.
- [57] Hui D, Qiang L, Jian W, Ti Z, Da-Lu K. A randomized, controlled trial of postoperative adjuvant cytokine-induced killer cells immunotherapy after radical resection of hepatocellular carcinoma. *Dig Liver Dis* 2009;41(1):36–41. doi:10.1016/j.dld.2008.04.007, PMID:18818130.
- [58] Yu X, Zhao H, Liu L, Cao S, Ren B, Zhang N, et al. A randomized phase II study of autologous cytokine-induced killer cells in treatment of hepatocellular carcinoma. *J Clin Immunol* 2014;34(2):194–203. doi:10.1007/s10875-013-9976-0, PMID:24337625.
- [59] Lee JH, Lee JH, Lim YS, Yeon JE, Song TJ, Yu SJ, et al. Adjuvant immunotherapy with autologous cytokine-induced killer cells for hepatocellular carcinoma. *Gastroenterology* 2015;148(7):1383–91.e6. doi:10.1053/j.gastro.2015.02.055, PMID:25747273.
- [60] Mo HY, Liao YY, You XM, Cucchetti A, Yuan BH, Li RH, et al. Timely meta-analysis on the efficacy of adoptive immunotherapy for hepatocellular carcinoma patients after curative therapy. *PLoS One* 2017;12(3):e0174222. doi:10.1371/journal.pone.0174222, PMID:28339493.
- [61] Zhong JH, Ma L, Wu LC, Zhao W, Yuan WP, Wu FX, et al. Adoptive immunotherapy for postoperative hepatocellular carcinoma: a systematic review. *Int J Clin Pract* 2012;66(1):21–27. doi:10.1111/j.1742-1241.2011.02814.x, PMID:22171902.
- [62] Finn RS, Qin S, Ikeda M, Galle PR, Ducreux M, Kim TY, et al. Atezolizumab plus Bevacizumab in Unresectable Hepatocellular Carcinoma. *N Engl J Med* 2020;382(20):1894–1905. doi:10.1056/NEJMoa1915745, PMID:32402160.
- [63] Kudo M, Ueshima K, Nakahira S, Nishida N, Ida H, Minami Y, et al. Adjuvant nivolumab for hepatocellular carcinoma (HCC) after surgical resection (SR) or radiofrequency ablation (RFA) (NIVOLVE): A phase 2 prospective multicenter single-arm trial and exploratory biomarker analysis. *J Clin Oncol* 2021;39(15_suppl):4070. doi:10.1200/JCO.2021.39.15_suppl.4070.
- [64] Li L, Wu PS, Liang XM, Chen K, Zhang GL, Su QB, et al. Adjuvant immune checkpoint inhibitors associated with higher recurrence-free survival in postoperative hepatocellular carcinoma (PREVENT): a prospective, multicenter cohort study. *J Gastroenterol* 2023;58(10):1043–1054. doi:10.1007/s00535-023-02018-2, PMID:37452107.
- [65] Qin S, Chen M, Cheng AL, Kaseb AO, Kudo M, Lee HC, et al. Atezolizumab versus active surveillance in patients with resected or ablated high-risk hepatocellular carcinoma (IMbrave050): a randomised, open-label, multicentre, phase 3 trial. *Lancet* 2023;402(10415):1835–1847. doi:10.1016/S0140-6736(23)01796-8, PMID:37871608.
- [66] Yamamoto M, Arai S, Sugahara K, Tobe T. Adjuvant oral chemotherapy to prevent recurrence after curative resection for hepatocellular carcinoma. *Br J Surg* 1996;83(3):336–340. doi:10.1002/bjs.1800830313, PMID:8665186.
- [67] Hasegawa K, Takayama T, Ijichi M, Matsuyama Y, Imamura H, Sano K, et al. Uracil-tegafur as an adjuvant for hepatocellular carcinoma: a randomized trial. *Hepatology* 2006;44(4):891–895. doi:10.1002/hep.21341, PMID:17006925.
- [68] Ishizuka M, Kubota K, Nemoto T, Shimoda M, Kato M, Iso Y, et al. Administration of adjuvant oral tegafur/uracil chemotherapy post hepatocellular carcinoma resection: A randomized controlled trial. *Asian J Surg* 2016;39(3):149–154. doi:10.1016/j.asjsur.2015.04.008, PMID:26123137.
- [69] Xia Y, Qiu Y, Li J, Shi L, Wang K, Xi T, et al. Adjuvant therapy with capecitabine postpones recurrence of hepatocellular carcinoma after curative resection: a randomized controlled trial. *Ann Surg Oncol* 2010;17(12):3137–3144. doi:10.1245/s10434-010-1148-3, PMID:20602260.
- [70] Zhong J, Xiang B, Ma L, Li L. Conventional oral systemic chemotherapy for postoperative hepatocellular carcinoma: A systematic review. *Mol Clin Oncol* 2014;2(6):1091–1096. doi:10.3892/mco.2014.337, PMID:25279203.
- [71] Li JX, Zhang RJ, Qiu MQ, Yan LY, He ML, Long MY, et al. Non-classic radiation-induced liver disease after intensity-modulated radiotherapy for Child-Pugh grade B patients with locally advanced hepatocellular carcinoma. *Radiat Oncol* 2023;18(1):48. doi:10.1186/s13014-023-02232-5, PMID:36890592.
- [72] Chiang CL, Chiu KWH, Chan KSK, Lee FAS, Li JCB, Wan CWS, et al. Sequential transarterial chemoembolisation and stereotactic body radiotherapy followed by immunotherapy as conversion therapy for patients with locally advanced, unresectable hepatocellular carcinoma (START-FIT): a single-arm, phase 2 trial. *Lancet Gastroenterol Hepatol* 2023;8(2):169–178. doi:10.1016/S2468-1253(22)00339-9, PMID:36529152.
- [73] Yu W, Wang W, Rong W, Wang L, Xu Q, Wu F, et al. Adjuvant radiotherapy in centrally located hepatocellular carcinomas after hepatectomy with narrow margin (<1 cm): a prospective randomized study. *J Am Coll Surg* 2014;218(3):381–392. doi:10.1016/j.jamcollsurg.2013.11.030, PMID:24559953.
- [74] Chen B, Wu JX, Cheng SH, Wang LM, Rong WQ, Wu F, et al. Phase 2 Study of Adjuvant Radiotherapy Following Narrow-Margin Hepatectomy

- in Patients With HCC. *Hepatology* 2021;74(5):2595–2604. doi:10.1002/hep.31993, PMID:34097307.
- [75] Wang L, Qiu L, Ke Q, Ji H, Wu J. Systematic review of adjuvant external beam radiotherapy for hepatocellular carcinoma following radical hepatectomy. *Radiother Oncol* 2022;175:101–111. doi:10.1016/j.radonc.2022.08.019, PMID:35998838.
- [76] Lau WY, Leung TW, Ho SK, Chan M, Machin D, Lau J, *et al*. Adjuvant intra-arterial iodine-131-labelled lipiodol for resectable hepatocellular carcinoma: a prospective randomised trial. *Lancet* 1999;353(9155):797–801. doi:10.1016/s0140-6736(98)06475-7, PMID:10459961.
- [77] Lau WY, Lai EC, Leung TW, Yu SC. Adjuvant intra-arterial iodine-131-labeled lipiodol for resectable hepatocellular carcinoma: a prospective randomized trial-update on 5-year and 10-year survival. *Ann Surg* 2008;247(1):43–48. doi:10.1097/SLA.0b013e3181571047, PMID:18156922.
- [78] Chung AY, Ooi LL, Machin D, Tan SB, Goh BK, Wong JS, *et al*. Adjuvant hepatic intra-arterial iodine-131-lipiodol following curative resection of hepatocellular carcinoma: a prospective randomized trial. *World J Surg* 2013;37(6):1356–1361. doi:10.1007/s00268-013-1970-4, PMID:23463394.
- [79] Yamamoto T, Nakamura H, Liu W, Cao K, Yoshikawa S, Enomoto H, *et al*. Involvement of hepatoma-derived growth factor in the growth inhibition of hepatocellular carcinoma cells by vitamin K(2). *J Gastroenterol* 2009;44(3):228–235. doi:10.1007/s00535-008-2304-4, PMID:19214667.
- [80] Mizuta T, Ozaki I, Eguchi Y, Yasutake T, Kawazoe S, Fujimoto K, *et al*. The effect of menatetrenone, a vitamin K2 analog, on disease recurrence and survival in patients with hepatocellular carcinoma after curative treatment: a pilot study. *Cancer* 2006;106(4):867–872. doi:10.1002/cncr.21667, PMID:16400650.
- [81] Hotta N, Ayada M, Sato K, Ishikawa T, Okumura A, Matsumoto E, *et al*. Effect of vitamin K2 on the recurrence in patients with hepatocellular carcinoma. *Hepatogastroenterology* 2007;54(79):2073–2077. PMID:18251162.
- [82] Kakizaki S, Sohara N, Sato K, Suzuki H, Yanagisawa M, Nakajima H, *et al*. Preventive effects of vitamin K on recurrent disease in patients with hepatocellular carcinoma arising from hepatitis C viral infection. *J Gastroenterol Hepatol* 2007;22(4):518–522. doi:10.1111/j.1440-1746.2007.04844.x, PMID:17376044.
- [83] Yoshiji H, Noguchi R, Toyohara M, Ikenaka Y, Kitade M, Kaji K, *et al*. Combination of vitamin K2 and angiotensin-converting enzyme inhibitor ameliorates cumulative recurrence of hepatocellular carcinoma. *J Hepatol* 2009;51(2):315–321. doi:10.1016/j.jhep.2009.04.011, PMID:19501932.
- [84] Yoshida H, Shiratori Y, Kudo M, Shiina S, Mizuta T, Kojiro M, *et al*. Effect of vitamin K2 on the recurrence of hepatocellular carcinoma. *Hepatology* 2011;54(2):532–540. doi:10.1002/hep.24430, PMID:21574174.
- [85] Ishizuka M, Kubota K, Shimoda M, Kita J, Kato M, Park KH, *et al*. Effect of menatetrenone, a vitamin K2 analog, on recurrence of hepatocellular carcinoma after surgical resection: a prospective randomized controlled trial. *Anticancer Res* 2012;32(12):5415–5420. PMID:23225445.
- [86] Zhong JH, Mo XS, Xiang BD, Yuan WP, Jiang JF, Xie GS, *et al*. Postoperative use of the chemopreventive vitamin K2 analog in patients with hepatocellular carcinoma. *PLoS One* 2013;8(3):e58082. doi:10.1371/journal.pone.0058082, PMID:23505456.
- [87] Chen Q, Shu C, Laurence AD, Chen Y, Peng BG, Zhen ZJ, *et al*. Effect of Huaier granule on recurrence after curative resection of HCC: a multicentre, randomised clinical trial. *Gut* 2018;67(11):2006–2016. doi:10.1136/gutjnl-2018-315983, PMID:29802174.
- [88] Korean Liver Cancer Association (KLCA) and National Cancer Center (NCC) Korea. 2022 KLCA-NCC Korea practice guidelines for the management of hepatocellular carcinoma. *Clin Mol Hepatol* 2022;28(4):583–705. doi:10.3350/cmh.2022.0294, PMID:36263666.
- [89] Benson AB, D'Angelica MI, Abbott DE, Anaya DA, Anders R, Are C, *et al*. *Hepatocellular Cancers, Version 1.2023, NCCN Clinical Practice Guidelines in Oncology*. Available from: https://www.nccn.org/login?ReturnURL=https://www.nccn.org/professionals/physician_gls/pdf/hcc.pdf. 2023.
- [90] Vogel A, Cervantes A, Chau I, Daniele B, Llovet JM, Meyer T, *et al*. Correction to: "Hepatocellular carcinoma: ESMO Clinical Practice Guidelines for diagnosis, treatment and follow-up". *Ann Oncol* 2019;30(5):871–873. doi:10.1093/annonc/mdy510, PMID:30715202.
- [91] Li JR, Yang DL, Wang JM, Tian W, Wei W, Luo CP, *et al*. Importance of optimizing duration of adjuvant immune checkpoint inhibitor therapy to treat postoperative hepatocellular carcinoma after conversion therapy: a case report. *J Surg Case Rep* 2023;2023(11):rjad610. doi:10.1093/jscr/rjad610, PMID:37965538.
- [92] Kwee S, Chen X. Immunotherapy biomarkers for HCC: contemporary challenges and emerging opportunities. *Hepatology Res* 2022;8:32. doi:10.20517/2394-5079.2022.58, PMID:36120489.
- [93] Zhong JH. Adjuvant therapy for hepatocellular carcinoma: Dilemmas at the start of a new era. *World J Gastroenterol* 2024;30(8):806–810. doi:10.3748/wjg.v30.i8.806, PMID:38516235.
- [94] Stefanini B, Ielasi L, Chen R, Abbati C, Tonnini M, Tovoli F, *et al*. TKIs in combination with immunotherapy for hepatocellular carcinoma. *Expert Rev Anticancer Ther* 2023;23(3):279–291. doi:10.1080/14737140.2023.2181162, PMID:36794716.
- [95] Li MJ, Teng YX, Xie S, Ma L, Li LQ, Xiang BD, *et al*. Comparison of survival rates as predicted by total tumor volume or tumor burden score in patients with hepatocellular carcinoma concurrent with fatty liver disease and hepatitis B virus. *Expert Rev Gastroenterol Hepatol* 2023;17(5):499–507. doi:10.1080/17474124.2023.2196403, PMID:36975382.
- [96] Chan AWH, Zhong J, Berhane S, Toyoda H, Cucchetti A, Shi K, *et al*. Development of pre and post-operative models to predict early recurrence of hepatocellular carcinoma after surgical resection. *J Hepatol* 2018;69(6):1284–1293. doi:10.1016/j.jhep.2018.08.027, PMID:30236834.
- [97] Wu M, Liu L, Wang X, Xiao Y, Yang S, Dong J. Radiomic features on contrast-enhanced images of the remnant liver predict the prognosis of hepatocellular carcinoma after partial hepatectomy. *iLIVER* 2024;3(1):100079. doi:10.1016/j.iliver.2024.100079.